



Review

Human Soil-transmitted Helminths and Lung Infections: A Guide Review for Respiratory Therapists

Majed H.M. Wakid^{1,2,*}

¹Department of Medical Laboratory Technology, Faculty of Applied Medical Sciences, King Abdulaziz University, Jeddah, Saudi Arabia

²Special Infectious Agents Unit, King Fahd Medical Research Center, Jeddah, Saudi Arabia

ARTICLE INFO

Article History

Received 14 April 2020

Accepted 04 September 2020

Keywords

Parasites
soil-transmitted helminths
Ascaris lumbricoides
hookworm
Strongyloides stercoralis
lung
global health

ABSTRACT

Soil-transmitted helminths are among the neglected tropical diseases, although some 1.5 billion individuals are affected. Traveling to endemic regions, global immigration, and increase of immunocompromised cases, in addition to other factors, have an influence on global susceptibility to these parasites. These helminth parasites can affect the human respiratory system during their life cycles either directly or indirectly. A better understanding of all aspects related to these parasites will assist respiratory therapists in putting together a proper diagnosis and management. This review covers the morphology, life cycles, epidemiology, clinical aspects, glance about laboratory diagnosis, and control of soil-transmitted helminths.

© 2020 Dr. Sulaiman Al Habib Medical Group. Publishing services by Atlantis Press International B.V.
This is an open access article distributed under the CC BY-NC 4.0 license (<http://creativecommons.org/licenses/by-nc/4.0/>).

1. INTRODUCTION

Globally, the field of respiratory therapy is given more attention recently, and many universities established new bachelor programs among the Allied Medical Sciences Faculties. According to the World Health Organization (WHO), many parasitic infections are among the neglected tropical diseases. This review will be a start of a comprehensive series addressed to respiratory therapists to provide an overview of the important parasites involved as causative agents of lung infection. This paper discusses the soil-transmitted helminths and their impact on the lungs and other aspects.

The WHO estimated that globally more than 1.5 billion people are infected with soil-transmitted helminths. These helminths, which are roundworms related to the Phylum Nematoda, have among the highest infection rates in man, especially in tropical and subtropical areas [1]. Contaminated soil plays a vital role in these worms' transmission and life cycles. The soil-transmitted helminths include *Ascaris lumbricoides*, hookworm (*Ancylostoma duodenale* and *Necator americanus*), *Strongyloides stercoralis*, and *Trichuris trichiura*. The first three parasites are commonly associated with lung infection and will be covered in this review (Figure 1). Very rare instances of pneumonitis caused by *T. trichiura* may occur when larvae penetrate the intestinal tissues and by way of the lymph and blood vessels reach the lungs [2].

*Email: mwakid@kau.edu.sa

Peer review under responsibility of the Dr. Sulaiman Al Habib Medical Group

2. ASCARIS LUMBRICOIDES

2.1. Introduction and Epidemiology

Ascaris lumbricoides belongs to the Family Ascarididae of the Suborder Ascaridina. It is the largest intestinal nematoda roundworm (male, 15–30 cm; female, 20–35 cm) and among the common helminths that infect humans. According to the WHO, ascariasis affects about 1 billion people worldwide in endemic countries, mainly children and adolescents [3,4]. Infection with *A. lumbricoides* is cosmopolitan, mainly in tropical areas with poor sanitation and personal hygiene. Those who live in areas where wastewater is used for irrigation, people defecate outdoors, or human feces are used as fertilizer, are at high risk of infection associated with the consumption of raw vegetables. *Ascaris* infection in the community is not age-dependent and can affect children, as well as young and elderly populations [5].

2.2. Life Cycle and Modes of Infection

Ascaris lumbricoides transmission to humans is through direct fecal–oral transmission. It occurs mainly with soil contamination of hands or ingestion of contaminated foods or drinks containing mature second-stage larvated (embryonated) eggs. After hatching in the upper part of the small intestine, larvae penetrate the wall of intestinal mucosa, and transport to the vascular capillaries, then via the portal vein to the hepatic circulation. Some of the larvae can migrate to the liver directly through the intestinal wall. Larvae will

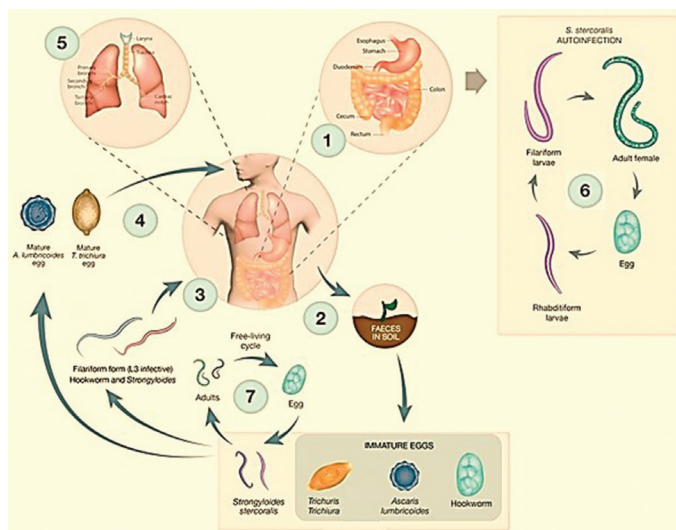


Figure 1 | Life cycles of the human soil-transmitted helminths. Reproduced with modification from Gordon et al. [98].

molt to the third stage, then proceed to the right side of the heart, then to the pulmonary circulation [6]. They stay for several days, then make a trip across the alveolar wall and tracheobronchial tree to the larynx and esophagus to the small intestine. Here, larvae molt into the fourth stage and then finally become adults. After copulation, adult female worms begin to produce fertilized (fertile) eggs. Meanwhile, unfertilized (infertile) eggs can be seen in cases with absence of adult male worms. Fertilized eggs can survive and stay viable for several months or years depending on the surrounding warm and moist condition [3,5,6].

2.3. Pathology and Clinical Aspects

Most intestinal ascariasis cases are asymptomatic or with limited symptoms. Symptomatic cases depend on the worm burden especially in children. The common nonspecific symptoms include abdominal pain, diarrhea, weight loss, weakness, and anorexia [7]. Complications related to ascariasis may include anemia caused by upper gastrointestinal bleeding, intestinal obstruction, intestinal peritonitis, pancreatitis, acute appendicitis, acute cholecystitis, gastric ascariasis, and hematemesis [8–10].

When larvae accumulate in the lung during the second week of infection, eosinophilic pneumonia, or Loeffler syndrome, may occur because of hypersensitivity reactions to larval stages. Light infection is usually asymptomatic. The main symptoms of heavy infections include chest pain, dry cough, dyspnea with abnormal breath sounds, bloody sputum (hemoptysis), and in rare cases, pleuritis or pleural effusion. In addition, respiratory failure was associated with ascariasis in immunodeficient patients. Some larvae can cause complications in other parts of the body. This could lead to granulomatous peritonitis, atopic dermatitis, and eye infection [11–17].

2.4. Diagnosis

The diagnosis of intestinal ascariasis depends on the macroscopic detection of adult worms in stool sample, in addition to microscopic

identification of eggs (fertilized or/and unfertilized) using direct smears, thick smears, sedimentation and flotation techniques. Abdomen ultrasonography, Computed Tomography (CT), magnetic resonance imaging, and X-ray can show the adult worms of *A. lumbricoides* in the gut.

Immunoglobulin IgG4 antibodies against *Ascaris* hemoglobin could be used as a supportive marker for diagnosis [18,19].

Chest CT and radiographs may illustrate bilateral pleural effusion, consolidation, patchy alveolar infiltrates, and unilateral or bilateral transient migratory fleeting nonsegmental opacities of various sizes often peripherally situated [20–23]. Examination of sputum, bronchoalveolar specimens or gastric secretions may detect larvae, eosinophils, and Charcot–Leyden crystals. Elevated levels of total serum Immunoglobulin E (IgE) are associated with several parasitic infections including *Ascaris* larval infection [24,25].

3. HOOKWORM

3.1. Introduction and Epidemiology

Human hookworm includes two species: *A. duodenale* and *N. americanus*. They get their common name from the hook-like teeth in the mouth part of adult worms. Hookworms are classified under the Suborder Strongylina and Family Ancylostomatidae. Hookworms infect an estimated 450–740 million people worldwide [4,26]. The size of adult worms is about 1 cm long (male, 8–11 mm; female, 10–13 mm). *A. duodenale* is distributed more focally, although its common name is “Old World hookworm.” The sizes of male and female adult worms are 7–9 and 9–11 mm, respectively, being a little smaller than the preceding species. Although the common name of *N. americanus* is “New World hookworm,” this species widely found across developing regions of South Asia and sub-Saharan Africa. In several studies, both species coexisted in the same region with higher prevalence for *N. americanus* [27]. Infection with hookworms starts gradually from childhood and reaches the highest level during late teens and early adulthood. Intensity stabilization then begins during all age levels unless effective control measures are involved [28–31].

In general, the severity of iron deficiency anemia and protein malnutrition caused by hookworms depends on the amount of blood loss [32], which is associated with the worm burden, and depends on the nutritional and iron status of the host prior to the infection.

3.2. Life Cycle and Modes of Infection

Humans are the principal final hosts of hookworms, and infected persons pass thousands of eggs in feces daily. Eggs mature in soil or any favorable warm moist conditions outside the host, forming rhabditiform larvae (L1 and L2) and finally filariform larvae (L3). Humans become infected via skin penetration (transcutaneous) with L3 through bare feet (mainly *N. americanus*) or via the oral route in the case of *A. duodenale*. As in the case of *A. lumbricoides*, the larvae migrate through blood or lymph stream to the heart and lungs. Larvae reach the small intestine after penetrating the alveolar wall to the trachea, esophagus, and stomach. The larvae molt and become mature adult worms in the small intestine within 2 months, and are soon ready to start lay eggs [31].

3.3. Pathology and Clinical Aspects

First, cutaneous dermatitis is caused during larval skin penetration. A red itchy papule is formed at the site of each penetration, the so-called “ground itch.” Scratching leads to secondary bacterial infection and formation of pustules. In rare cases, in heavy infections with extensive lesions the patients suffer from *creeping eruption* [33].

Filariform larvae that break through the pulmonary capillaries can cause bronchitis and bronchopneumonia. Larvae migration through pulmonary tissue may cause Loeffler syndrome, with fever, cough, wheezing, dyspnea, and hemoptysis [34]. Ingestion of a high number of larvae causes Wakana syndrome, which is characterized by eosinophilia and symptoms such as pneumonitis [26].

Adult worms inhabit the small intestine, mainly the upper part of the jejunum, biting the intestinal wall and sucking the mucosa with the cutting plates (*N. americanus*) or ventral teeth (*A. duodenale*). Symptoms are associated with continuous blood loss, intestinal inflammation, and mucosa necrosis. The patient may suffer from abdominal pain, diarrhea, fecal occult blood, and occasionally melena. In continuous blood loss in heavy infected cases, the patient suffers from severe iron deficiency, anemia with fatigue, short breath, headache, koilonychia, and rarely allotriophagy [35–40].

3.4. Diagnosis

Laboratory diagnosis during pulmonary infection depends on the detection and identification of L3 filariform larvae in sputum or bronchoalveolar lavage. Chest radiographs demonstrate transient pulmonary infiltrates, bronchitis, and transient nonsegmental consolidation [41].

Diagnosis of intestinal infection relies mainly on the detection of eggs in stool using direct iodine and concentration techniques [42,43]. In addition, rhabditiform and, in rare cases, filariform larvae can be observed in stool samples of constipation cases or delayed samples. Specimens from duodenum using Entero-capsule (duodenal string test) may detect the eggs and larvae [44].

4. STRONGYLOIDES STERCORALIS

4.1. Introduction and Epidemiology

This “threadworm” is the smallest intestinal nematode. *S. stercoralis* are classified under the Suborder Rhabditina and Family Strongyloididae. The female adult worms occur in two different phases; the free living (1 mm × 65 µm) including the entire life cycle in the soil, and the parasitic (2 mm × 35 µm) generations in man, whereas all male adults (0.7 mm × 40 µm) are free living [45,46]. According to the WHO, strongyloidiasis affects up to 600 million people globally, and the risk of infection is associated with hygiene and walking barefoot, making children especially vulnerable to infection. Strongyloidiasis is among the most neglected tropical diseases, but was recently given more attention according to the WHO 2030 global target [1]. Infection with *Strongyloides* is not restricted to tropical and subtropical countries; it also seems to be endemic in temperate regions [47]. The infection could be serious in immunosuppression cases, certain malignancies, human T-cell lymphotropic virus type 1 infection, and alcoholism [48–53].

4.2. Life Cycle and Modes of Infection

The females of parasitic generations in infected final hosts inhabiting the mucosa of the duodenum or the jejunum lay eggs by parthenogenesis. These eggs grow promptly and hatch to become rhabditiform larvae (R-form) then pass in the stool. If the patient suffers from constipation or immunodeficiency, unpassed out R-form become infective filariform larvae (F-form), which invade the intestinal walls leading to internal autoinfection. Rarely in unclean persons, the larvae may penetrate the perianal skin leading to external autoinfection. Both types of autoinfection enable persistent infection for several years without any extrinsic exposure [48,54]. Meanwhile, under favorable conditions in soil, R-form passed in stool will continue the free living life cycle forming both male and female adult worms. Female worms then lay eggs, which mature and give rise exclusively to female R-form, then become infective F-form. These can infect humans both percutaneously (by penetration of the skin of the foot) and orally (by ingestion) [55,56], then enter the bloodstream and proceed to the heart and thereafter to the lung. The larvae migrate from the alveoli to the trachea, esophagus, stomach, then the mucosa of the small intestine, mainly in the duodenum, where they mature to female adult worms.

4.3. Pathology and Clinical Aspects

Percutaneous invasion by F-form larvae may give rise to dermatitis at the site of penetration. Like hookworm, itching and erythema are noticed, but in some cases, larvae can move over intracutaneously leading to “creeping eruption” [57–59].

Strongyloides stercoralis larvae gathering in the pulmonary tissue can cause cough and appear in the sputum. In addition, patients may present Loeffler syndrome with eosinophilia, hypoalbuminemia, and elevated IgE. This can lead to dyspnea, bronchopneumonia, and massive bleeding caused by alveolar hemorrhage [60]. Acute Respiratory Distress Syndrome (ARDS) and septicemia related to intestinal transmural migration of bacteria can occur as a result of pulmonary hyperinfection or disseminated strongyloidiasis [61–63]. In addition, acute anemia, acute renal failure, and systemic inflammatory response syndrome are also reported in hyperinfection [64–66].

Symptoms of intestinal infection include diarrhea, abdominal discomfort, upper abdominal pain, and fever. In heavy chronic autoinfection cases, nausea, mucous with bloody stool, and anemia are seen. These symptoms are related to the destruction, damage, and mucosal inflammation caused by the adult and larval stages of the parasite, particularly in the duodenum and jejunum, but may take place in the bile and pancreatic ducts. In immunosuppressed patients, autoinfection progresses further to hyperinfection (in the lung and intestine) and disseminates into multiple organs, mainly the liver, brain, heart, and urinary tract [67–71]. Hyperinfection can become severe and even fatal or occur decades after the initial infection [72–75]. This is related to a deficient T helper 2 (Th2) immune response, so it is difficult to control the multiplication of huge number of larvae. Additional ulcers/lesion caused by F-form larvae, with possible destruction of muscular layers, which may lead to perforation, are also seen [76,77].

4.4. Diagnosis

During pulmonary involvement, chest X-ray, and CT findings include patchy, migratory airspace consolidation, with areas of cavitation with irregular walls. A miliary pattern has also been reported [78–81]. Sputum, bronchoalveolar lavage can be examined microscopically for larvae detection [82–85].

Stool is the best sample for laboratory diagnosis of intestinal infection. The main applicable techniques for detection of R-form larvae (the common diagnostic stage) are wet mount preparation and sedimentation techniques. Rarely, in certain cases, F-form larvae, adult worms, and eggs can be detected in stool samples. Moreover, several fecal cultures are available, but infrequently used. Duodenal specimens using Entero-Test are useful for detection of eggs, larvae, and/or parasitic female adult worms [44,86].

Hyperinfection cases can be diagnosed by identifying female adult worms, R-form larvae, F-form larvae, or eggs in biopsies from the affected organs. Enzyme-linked immunosorbent assay and polymerase chain reaction of blood and cerebrospinal fluid have shown reasonable results [87].

5. IMMUNE RESPONSE

Helminths antigens or helminth-derived Excretory/Secretory (ES) activate dendritic cells, which act as antigen-presenting cells, presenting the antigen to T cells to commence an immune response mediated by Th2 cells [88–91]. There are multiple mechanisms in which helminths trigger a type 2 immune response through the lymphatic/circulatory system. Prior to adult stages formation and establishment, the infective larvae invade the lungs or intestinal mucosa. This damage triggers tuft cells and other epithelial cells to secrete a group of alarmins, including thymic stromal lymphopoeitin, Interleukin-33 (IL-33), and IL-25. These alarmins then promote the activation and differentiation of type 2 innate lymphoid cells and CD4 Th2 cells, leading to the release of many cytokines. IL-5 promotes eosinophilia, and in integration with IL-4, IL-9, and IL-13, in addition to IgE, which bind with high-affinity with Fc epsilon receptor, leading to activation of mast cells and basophils and release of inflammatory mediators (e.g., histamine and heparin). Furthermore, IL-4 and IL-13 lead to an increased contractility of

smooth muscle cells, goblet cells, hypersecretion of mucus, and enhance intestinal permeability to help expulsion of adult parasites in the lumen. In addition, IL-4 and IL-13 activate the alternative activated macrophages, which inactivate the production of Th1, Th2, and Th17. These cytokines also promote isotype class switching in B cells to produce IgG.

6. CONTROL OF SOIL-TRANSMITTED HELMINTHS

The main key in adapting control programs for any parasite is to understand the life cycle and modes of infection. In simple terms, the goal of any control program is to cut or interrupt the life cycle of the parasite.

The first line of soil-transmitted helminthiasis control is treatment of infected people. The WHO supports and recommends regular and mass treatment using drugs such as albendazole, mebendazole, and ivermectin [1,6,92,93]. The WHO's global target for morbidity control is to eliminate soil-transmitted helminths as a public health problem by the end of 2020 [94].

Second, use of educational materials to provide information about the modes of infections is very effective in reducing disease burden and prevention of infection. Awareness about proper disposal of fecal matter/use of latrines/avoid soil contamination, use of footwear, washing hands, proper food preparation, consumption of washed food, and eliminating the use of untreated human feces as fertilizer, are examples related to these fecal-borne parasites [95,96]. Improvement in water, sanitation, and hygiene has important short- and long-term impacts on infection rates. As these parasites can be transmitted to humans directly or indirectly, the community should therefore be supplied with information, particularly on appropriate sanitation and hygiene standards and cleanliness practices [95–97].

In addition, we believe that the role of large-scale screening by accurate clinical/diagnostic techniques and involving well-trained physicians/respiratory therapists/laboratory technologists have a significant impact on the management and control programs.

Table 1 outlines the symptoms, signs, investigation, and treatment of human soil-transmitted helminths involved in lung diseases.

Table 1 | Overview of soil-transmitted helminths and human lung infections

Parasite	Mode of infection	Clinical presentation	Radiological features	Laboratory tests	Treatment
<i>Ascaris lumbricoides</i>	Ingestion of larvated eggs in contaminated food or drink (fecal–oral)	Eosinophilic pneumonia, cough, wheeze, dyspnea, hemoptysis	Transient nodular or diffuse pulmonary infiltrates, basal opacities, spontaneous pneumothorax	Stool: adult worms and eggs Pulmonary: larvae Blood: eosinophilia	Mebendazole and albendazole
Hookworm	L3 larval skin penetration (and oral route in case of <i>A. duodenale</i>)	Eosinophilic pneumonia, cough, wheeze, dyspnea	Bronchitis, bronchopneumonia, transient pulmonary infiltrates, transient nonsegmental areas of consolidation	Stool: eggs and larvae Pulmonary: larvae Blood: eosinophilia	Mebendazole and albendazole
<i>Strongyloides stercoralis</i>	L3 larval skin penetration	Eosinophilic pneumonia, chest pain, fever, cough, wheeze, dyspnea, hyperinfection syndrome, ARDS, intra-alveolar hemorrhage	Bronchopneumonia, pulmonary infiltrates, miliary nodules, airspace opacities ARDS in severe disease, rarely granulomatous changes	Stool or duodenal specimens: larvae Pulmonary: larvae Blood: eosinophilia	Ivermectin and albendazole

CONFLICTS OF INTEREST

The author declares no conflicts of interest.

REFERENCES

- [1] World Health Organization (WHO). Soil-transmitted helminth infections. Available from: <https://www.who.int/en/news-room/fact-sheets/detail/soil-transmitted-helminth-infections> (accessed February 15, 2020).
- [2] Tahseen Q. Soil-transmitted helminths and water. In: Singh P, Sharma V, editors. *Water and health*. New Delhi: Springer; 2014, pp. 275–303.
- [3] Centers for Disease Control and Prevention (CDC). Ascariasis. Available from: <https://www.cdc.gov/parasites/ascariasis/index.html> (accessed February 15, 2020).
- [4] GBD 2017 Disease and Injury Incidence and Prevalence Collaborators. Global, regional, and national incidence, prevalence, and years lived with disability for 354 diseases and injuries for 195 countries and territories, 1990–2017: a systematic analysis for the global burden of disease study 2017. *Lancet* 2018;392:1789–858.
- [5] Scott ME. *Ascaris lumbricoides*: a review of its epidemiology and relationship to other infections. *Ann Nestlé* 2008;66:7–22.
- [6] Brooker SJ BD. Soil-transmitted helminths (Geohelminths). In: Farrar J, Hotez P, Junghans T, Kang G, Lalloo DG, White NJ, editors. *Manson's tropical diseases*. 23rd ed. Philadelphia: Elsevier Saunders; 2014, pp. 766–76.
- [7] Lloyd AE, Honey BL, John BM, Condren M. Treatment options and considerations for intestinal helminthic infections. *J Pharm Technol* 2014;30:130–9.
- [8] Das AK. Hepatic and biliary ascariasis. *J Glob Infect Dis* 2014;6:65–72.
- [9] Khuroo NS, Khuroo MS, Khuroo MS. Gastric ascariasis presenting as unique dyspeptic symptoms in an endemic area. *Am J Gastroenterol* 2010;105:1675–7.
- [10] Ahmad MM, Malik PK, Hassan S, Dwivedi S. Ascariasis presenting as hematemesis in a young boy. *J Health Res Rev* 2015;2:37–8.
- [11] Aleksandra L, Barbara Z, Natalia LA, Danuta KB, Renata GK, Ewa ML. Respiratory failure associated with ascariasis in a patient with immunodeficiency. *Case Rep Infect Dis* 2016;2016:4070561.
- [12] Souza AMDES, Barbuto TM, Freitas FA, Vianna NF, Zanchetta CMC, Forsait S, et al. An unusual abdominal wall mass in a child. *Rev Inst Med Trop Sao Paulo* 2017;59:e16.
- [13] Kanneganti K, Makker JS, Remy P. *Ascaris lumbricoides*: to expect the unexpected during a routine colonoscopy. *Case Rep Med* 2013;2013:579464.
- [14] Gutiérrez E, Ortiz B, Gallego A, Muñoz C. Granulomatous peritonitis due to *Ascaris lumbricoides*: case report. *Iatreia* 2008;21: 199–204 [Eng summary].
- [15] Qualizza R, Losappio LM, Furci F. A case of atopic dermatitis caused by *Ascaris lumbricoides* infection. *Clin Mol Allergy* 2018;16:10.
- [16] Janićević-Petrović MA, Šarenac-Vulović T, Vulović D, Janićević K, Popović A. Parasitic eye infection by *Ascaris lumbricoides*: case report. *Sanamed* 2014;9:181–4.
- [17] Balasubramaniam M, Sudhakar P, Subhashini M, Srinivasan S, Padma M, Chopra V. *Ascaris lumbricoides* in the lacrimal passage. *Indian J Ophthalmol* 2000;48:53–4.
- [18] Gowon AI, Baba OV, Baba OI, Akpu PA, Lynda AE. *Ascaris lumbricoides* using microscopy and IgG4 techniques in a school children in central Nigeria: an epidemiological study. *J Infec Dis Treat* 2018;4:1–5.
- [19] Santra A, Bhattacharya T, Chowdhury A, Ghosh A, Ghosh N, Chatterjee BP, et al. Serodiagnosis of ascariasis with specific IgG4 antibody and its use in an epidemiological study. *Trans R Soc Trop Med Hyg* 2001;95:289–92.
- [20] Elhadidy T, Eldesoqy ME, Morsy NE, Abdelwahab HW, Tohlob M. *Ascaris lumbricoides* through pleural biopsy needle. A rare case of intrapleural ascariasis. *Arch Bronconeumol* 2017;53:171–2.
- [21] Ekin S, Sertogullarindan B, Gunbatar H, Arisoy A, Yildiz H. Loeffler's syndrome: an interesting case report. *Clin Respir J* 2016;10:112–14.
- [22] Martínez S, Restrepo CS, Carrillo JA, Betancourt SL, Franquet T, Varón C, et al. Thoracic manifestations of tropical parasitic infections: a pictorial review. *Radiographics* 2005;25:135–55 [Erratum in 25:878].
- [23] Vijayan VK. Parasitic lung infections. *Curr Opin Pulm Med* 2009;15:274–82.
- [24] Takeuchi H, Khan AF, Yunus M, Hasan MI, Hawlader MDH, Takanashi S, et al. Anti-*Ascaris* immunoglobulin E associated with bronchial hyper-reactivity in 9-year-old rural Bangladeshi children. *Allergol Int* 2016;65:141–6.
- [25] Buendía E, Zakzuk J, Mercado D, Alvarez A, Caraballo L. The IgE response to *Ascaris* molecular components is associated with clinical indicators of asthma severity. *World Allergy Organ J* 2015;8:8.
- [26] Centers for Disease Control and Prevention (CDC). Hookworm. Available from: <https://www.cdc.gov/parasites/hookworm/index.html> (accessed February 20, 2020).
- [27] Wakid MH. Speciation of intestinal hookworm among Bangladeshi and Indian male workers in Jeddah, Saudi Arabia. *JKAU Med Sci* 2020;27:1–7.
- [28] World Health Organization (WHO). Report of the WHO informal consultation on hookworm infection and anemia in girls and women. Available from: https://apps.who.int/iris/bitstream/handle/10665/59548/WHO_CTD_SIP_96.1.pdf (accessed February 15, 2020).
- [29] Gandhi NS, Jizhang C, Khoshnood K, Fuying X, Shanwen L, Yaoru L, et al. Epidemiology of *Necator americanus* hookworm infections in Xiulongkan Village, Hainan Province, China: high prevalence and intensity among middle-aged and elderly residents. *J Parasitol* 2001;87:739–43.
- [30] Bethony J, Chen J, Lin S, Xiao S, Zhan B, Li S, et al. Emerging patterns of hookworm infections: influence of aging on the intensity of *Necator* infection in Hainan Province, People's Republic of China. *Clin Infect Dis* 2002;35:1336–44.
- [31] Hotez PJ, Brooker S, Bethony JM, Bottazzi ME, Loukas A, Xiao S. Hookworm infection. *N Engl J Med* 2004;351:799–807.
- [32] Rao VG, Aggrawal MC, Yadav R, Das SK, Sahare LK, Bondley MK, et al. Intestinal parasitic infections, anaemia and undernutrition among tribal adolescents of Madhya Pradesh. *Indian J Community Med* 2003;28:26–9.
- [33] Heukelbach J, Feldmeier H. Epidemiological and clinical characteristics of hookworm-related cutaneous larva migrans. *Lancet Infect Dis* 2008;8:302–9.
- [34] Hotez PJ. Hookworm infections. In: Guerrant RL, Walker DH, Weller PF, editors. *Tropical infectious diseases: principles, pathogens, & practice*. 3rd ed. Philadelphia, PA: Churchill Livingstone; 2011, pp. 799–804.

- [35] Tan X, Cheng M, Zhang J, Chen G, Liu D, Liu Y, et al. Hookworm infection caused acute intestinal bleeding diagnosed by capsule: a case report and literature review. *Korean J Parasitol* 2017;55:417–20.
- [36] Tariq M, Muzammil SM, Shaikh FA, Inam Pal KM. Hookworm infestation as a cause of melena and severe anaemia in farmer. *J Pak Med Assoc* 2017;67:327–9.
- [37] Barakat M, Ibrahim N, Nasr A. *In vivo* endoscopic imaging of ancylostomiasis-induced gastrointestinal bleeding: clinical and biological profiles. *Am J Trop Med Hyg* 2012;87:701–5.
- [38] Chhabra P, Bhasin DK. Hookworm-induced obscure overt gastrointestinal bleeding. *Clin Gastroenterol Hepatol* 2017;15:e161–e2.
- [39] Kalli T, Karamanolis, Triantafyllou, K. Hookworm infection detected by capsule endoscopy in a young man with iron deficiency. *Clin Gastroenterol Hepatol* 2011;9:e33.
- [40] Adhikari S, Sigdel KR, Paudyal B, Basnyat B. Nail the diagnosis. *Wilderness Environ Med* 2018;29:419–20.
- [41] Armstrong P, Wilson AG, Dee P, Hansell DM. Imaging of diseases of the chest. 3rd ed. St. Louis, MO: Mosby; 2000.
- [42] Wakid MH, Azhar EI, Zafar TA. Intestinal parasitic infection among food handlers in the holy city of Makkah during Hajj season 1428 Hegira (2007G). *JKAU Med Sci* 2009;16:39–52.
- [43] Wakid MH. Fecal occult blood test and gastrointestinal parasitic infection. *J Parasitol Res* 2010;2010:434801.
- [44] Khurana S, Sethi S. Laboratory diagnosis of soil transmitted helminthiasis. *Trop Parasitol* 2017;7:86–91.
- [45] Centers for Disease Control and Prevention (CDC). Strongyloidiasis. Available from: <https://www.cdc.gov/dpdx/strongyloidiasis/index.html> (accessed February 21, 2020).
- [46] Hong YH, Kim JW, Rheem IS, Kim JS, Kim SB, Chai JY, et al. Observation of the free-living adults of *Strongyloides stercoralis* from a human stool in Korea. *Infect Chemother* 2009;41:105–8.
- [47] Gétaz L, Castro R, Zamora P, Kramer M, Gareca N, Torrico-Espinoza MDC, et al. Epidemiology of *Strongyloides stercoralis* infection in Bolivian patients at high risk of complications. *PLoS Negl Trop Dis* 2019;13:e0007028.
- [48] Vazquez Guillamet LJ, Saul Z, Miljkovich G, Vilchez GA, Mendonca N, Gourinini V, et al. *Strongyloides stercoralis* infection among human immunodeficiency virus (HIV)-infected patients in the United States of America: a case report and review of literature. *Am J Case Rep* 2017;18:339–46.
- [49] Silva MLS, Inês EdJ, Souza ABdS, VMdS, Guimarães CM, Menezes ER, et al. Association between *Strongyloides stercoralis* infection and cortisol secretion in alcoholic patients. *Acta Trop* 2016;154:133–8.
- [50] Schär F, Trostorf U, Giardina F, Khieu V, Muth S, Marti H, et al. *Strongyloides stercoralis*: global distribution and risk factors. *PLoS Negl Trop Dis* 2013;7:e2288.
- [51] Machado ER, Teixeira EM, Gonçalves-Pires MDRF, Loureiro ZM, Araújo RA, Costa-Cruz JM. Parasitological and immunological diagnosis of *Strongyloides stercoralis* in patients with gastrointestinal cancer. *Scand J Infect Dis* 2008;40:154–8.
- [52] Mascarello M, Gobbi F, Angheben A, Gobbo M, Gaiera G, Pegoraro M, et al. Prevalence of *Strongyloides stercoralis* infection among HIV-positive immigrants attending two Italian hospitals, from 2000 to 2009. *Ann Trop Med Parasitol* 2011;105:617–23.
- [53] Mejia R, Nutman TB. Screening, prevention, and treatment for hyperinfection syndrome and disseminated infections caused by *Strongyloides stercoralis*. *Curr Opin Infect Dis* 2012;25:458–63.
- [54] Toledo R, Muñoz-Antoli C, Esteban JG. Strongyloidiasis with emphasis on human infections and its different clinical forms. *Adv Parasitol* 2015;88:165–241.
- [55] Albarqi MMY, Stoltzfus JD, Pilgrim AA, Nolan TJ, Wang Z, Kliewer SA, et al. Regulation of life cycle checkpoints and developmental activation of infective larvae in *Strongyloides stercoralis* by daftachronic acid. *PLoS Pathog* 2016;12:e1005358.
- [56] Geri G, Rabbat A, Mayaux J, Zafrani L, Chalumeau-Lemoine L, Guidet B, et al. *Strongyloides stercoralis* hyperinfection syndrome: a case series and a review of the literature. *Infection* 2015;43:691–8.
- [57] Martin SJ, Cohen PR, MacFarlane DF, Grossman ME. Cutaneous manifestations of *Strongyloides stercoralis* hyperinfection in an HIV-seropositive patient. *Skinmed* 2011;9:199–202.
- [58] Corte LD, da Silva MVS, Souza PRM. Simultaneous larva migrans and larva currens caused by *Strongyloides stercoralis*: a case report. *Case Rep Dermatol Med* 2013;2013:381583.
- [59] Ly MN, Bethel SL, Usmani AS, Lambert DR. Cutaneous *Strongyloides stercoralis* infection: an unusual presentation. *J Am Acad Dermatol* 2003;49:S157–S60.
- [60] Mohammed S, Bhatia P, Chhabra S, Gupta SK, Kumar R. Pulmonary hyperinfection with *Strongyloides stercoralis* in an immunocompetent patient. *Indian J Crit Care Med* 2019;23:481–3.
- [61] Nnaoma C, Chika-Nwosuh O, Engell C. The worm that clogs the lungs: *Strongyloides* hyper-infection leading to fatal acute respiratory distress syndrome (ARDS). *Am J Case Rep* 2019;20:377–80.
- [62] Nabeya D, Haranaga S, Parrott GL, Kinjo T, Nahar S, Tanaka T, et al. Pulmonary strongyloidiasis: assessment between manifestation and radiological findings in 16 severe strongyloidiasis cases. *BMC Infect Dis* 2017;17:320.
- [63] Ghoshal UC, Ghoshal U, Jain M, Kumar A, Aggarwal R, Misra A, et al. *Strongyloides stercoralis* infestation associated with septicemia due to intestinal transmural migration of bacteria. *J Gastroenterol Hepatol* 2002;17:1331–3.
- [64] Teixeira MCA, Inês EJ, Pacheco FTE, Silva RKNR, Mendes AV, Adorno EV, et al. Asymptomatic *Strongyloides stercoralis* hyperinfection in an alcoholic patient with intense anemia. *J Parasitol* 2010;96:833–5.
- [65] Chand T, Bansal A, Jasuja S, Sagar G. Pulmonary strongyloidiasis and hyperinfection in a renal transplant patient. *Lung India* 2016;33:692–4.
- [66] Gupta V, Bhatia S, Mridha AR, Das P, Khanna N. *Strongyloides stercoralis* hyperinfection: an often missed but potentially fatal cause of anemia and hypoalbuminemia in leprosy patients on long-term steroid therapy. *Indian J Dermatol Venereol Leprol* 2017;83:381–3.
- [67] Ofori E, Ramai D, Khan A, Xiao P, Reddy M, Shahzad G. Hepatobiliary strongyloidiasis presenting as an ampullary lesion on esophagogastroduodenoscopy/endoscopic ultrasound. *Gastroenterol Rep (Oxf)* 2019;7:367–70.
- [68] Makker J, Balar B, Niazi M, Daniel M. Strongyloidiasis: a case with acute pancreatitis and a literature review. *World J Gastroenterol* 2015;21:3367–75.
- [69] Jones N, Cocchiarella A, Faris K, Heard SO. Pancreatitis associated with *Strongyloides stercoralis* infection in a patient chronically treated with corticosteroids. *J Intensive Care Med* 2010;25:172–4.
- [70] Oktar N, Özer HM, Demirtaş E. Central nervous system *Strongyloides stercoralis*. A case report. *Turk Neurosurg* 2020;30:776–9.
- [71] Leonor P, Gladymar P, Elsy R, Aurora H, Julio C, Carlos G, et al. Urinary rhabditiform larvae of *Strongyloides stercoralis* in disseminated disease affecting a kidney-transplanted patient. *Rev Med Hered* 2016;27:35–40.

- [72] Tam J, Schwartz KL, Keystone J, Dimitrakoudis D, Downing M, Krajden S. Case report: central nervous system strongyloidiasis: two cases diagnosed antemortem. *Am J Trop Med Hyg* 2019;100:130–4.
- [73] Rose CE, Paciullo CA, Kelly DR, Dougherty MJ, Fleckenstein LL. Fatal outcome of disseminated strongyloidiasis despite detectable plasma and cerebrospinal levels of orally administered ivermectin. *J Parasitol Res* 2009;2009:818296.
- [74] Ebong I, Goez-Gutierrez E, Kerr D, Rammohan K. Case report: a rare case of fatal disseminated strongyloidiasis with central nervous system involvement in a white South Floridian HIV positive man. *Neurology* 2017;88;(16 Supplement);P2.328. [Abstract].
- [75] Rao S, Tsai H, Tsai E, Nakanishi Y, Bulat R. *Strongyloides stercoralis* hyperinfection syndrome as a cause of fatal gastrointestinal hemorrhage. *ACG Case Rep J* 2019;6:1–3.
- [76] Figueira CF, da Costa Gaspar MT, Cos LD, Ussami EY, Otoch JP, Felipe-Silva A. *Strongyloides stercoralis* hyperinfection associated with impaired intestinal motility disorder. *Autops Case Rep* 2015;5:27–34.
- [77] Oztürk G, Aydın B, Celebi F, Gürsan N. Gastric perforation caused by *Strongyloides stercoralis*: a case report. *Ulus Travma Acil Cerrahi Derg* 2011;17:90–2.
- [78] Esteban Ronda V, Franco Serrano J, Briones Urriaga ML. Pulmonary *Strongyloides stercoralis* infection. *Arch Bronchoneumol* 2016;52:442–3.
- [79] Hochegger B, Zanetti G, Marchiori E. *Strongyloides stercoralis* infection with a diffuse miliary pattern. *Arch Bronchoneumol* 2017;53:352–3.
- [80] Bae K, Jeon KN, Ha JY, Lee JS, Na BK. Pulmonary strongyloidiasis presenting micronodules on chest computed tomography. *J Thorac Dis* 2018;10:E612–E15.
- [81] Saradna A, Shenoy A, Ambesh P, Kamholz S. *Strongyloides* hyperinfection and miliary tuberculosis presenting with syndrome of inappropriate antidiuretic hormone secretion in a malnourished patient. *Cureus* 2018;10:e2349.
- [82] Mahdi AS, Molai M, Khamis FA, Petersen E, Balushi AA, Sviben M, et al. Case report of *Strongyloides stercoralis* hyperinfection – a lesson for the immunocompromised patients' treatment. *Croat J Infect* 2018;38:18–21.
- [83] Yee B, Chi NW, Hansen LA, Lee RR, U HS, Savides TJ, et al. *Strongyloides stercoralis* hyperinfection syndrome presenting as severe, recurrent gastrointestinal bleeding, leading to a diagnosis of cushing disease. *Am J Trop Med Hyg* 2015;93:822–7.
- [84] Zhao P, Maleki Z. *Strongyloides stercoralis* in bronchoalveolar lavage specimen processed as Prussian blue stain. *Diagn Cytopathol* 2013;41:141–3.
- [85] Fernandez L, Gonzalez A, Sua L, Badiel M. *Strongyloides* hyperinfection diagnosed by bronchoalveolar lavage in a university medical center in South America. *Eur Respir J* 2013;42:4410.
- [86] Garcia LS, Arrowood M, Kokoskin E, Paltridge GP, Pillai DR, Procop GW, et al. Practical guidance for clinical microbiology laboratories: laboratory diagnosis of parasites from the gastrointestinal tract. *Clin Microbiol Rev* 2017;31:e00025–17.
- [87] Van De N, Minh PN, Van Duyet L, Mas-Coma S. Strongyloidiasis in northern Vietnam: epidemiology, clinical characteristics and molecular diagnosis of the causal agent. *Parasit Vectors* 2019;12:515.
- [88] Ditgen D, Anandarajah EM, Meissner KA, Brattig N, Wrenger C, Liebau E. Harnessing the helminth secretome for therapeutic immunomodulators. *Biomed Res Int* 2014;2014:964350.
- [89] Gazzinelli-Guimaraes PH, Nutman TB. Helminth parasites and immune regulation. *F1000Res* 2018;7:1685.
- [90] Montaner S, Galiano A, Trelis M, Martin-Jaular L, Del Portillo HA, Bernal D, et al. The role of extracellular vesicles in modulating the host immune response during parasitic infections. *Front Immunol* 2014;5:433.
- [91] Maizels RM, Hewitson JP, Smith KA. Susceptibility and immunity to helminth parasites. *Curr Opin Immunol* 2012;24:459–66.
- [92] World Health Organization (WHO). Intestinal worms. Available from: https://web.archive.org/web/20180422072147/http://www.who.int/intestinal_worms/resources/faqs/en/index1.html (accessed February 22, 2020).
- [93] The Medical Letter. Drugs for parasitic infections. Available from: https://www.uab.edu/medicine/gorgas/images/docs/syllabus/2015/03_Parasites/RxParasitesMedicalLetter2013.pdf (accessed February 15, 2020).
- [94] World Health Organization (WHO). Progress report 2001–2010 and strategic plan 2011–2020. Available from: https://apps.who.int/iris/bitstream/handle/10665/44804/9789241503129_eng.pdf (accessed February 22, 2020).
- [95] Mascarini-Serra L. Prevention of soil-transmitted helminth infection. *J Glob Infect Dis* 2011;3:175–82.
- [96] World Health Organization (WHO). Helminth control. Available from: https://apps.who.int/iris/bitstream/handle/10665/44671/9789241548267_eng.pdf. (accessed February 22, 2020).
- [97] Mduluza T, Chisango TJ, Nhidza AF, Marume A. Global control efforts of schistosomiasis and soil-transmitted helminthiasis, 2017. Available from: <https://www.intechopen.com/books/human-helminthiasis/global-control-efforts-of-schistosomiasis-and-soil-transmitted-helminthiasis> (accessed September 15, 2020).
- [98] Gordon CA, Kurscheid J, Jones MK, Gray DJ, McManus DP. Soil-transmitted helminths in Tropical Australia and Asia. *Trop Med Infect Dis* 2017;2:56.