

Functional hemispherectomy for the treatment of intractable seizures

John P. Girvin, PhD, FRCSC, Saleh S. Baeesa, MBChB, FRCSC.

ABSTRACT

Hemispherectomy is the most successful operation for the control of seizures in a very select group of patients with infantile hemiplegia and intractable epilepsy. The efficacy of anatomical hemispherectomy has been offset to some degree by the fact that up to one third of those operated upon will subsequently develop obstructive hydrocephalus, and the so-called superficial subpial cerebral hemosiderosis, with potentially fatal complications. This review article details the operative technique of a modified "functional" hemispherectomy. In essence, the technique consists of removing the central (Rolandic) cortex and the temporal lobe of the affected hemisphere and leaving the remainder of the hemisphere intact, but neurogenically disconnected from the remaining brain.

Neurosciences 2006; Vol. 11 (2): 72-77

To the best of current knowledge, the first hemispherectomy (HSPY) was undertaken in 1923 by Dr. Walter Dandy.¹ It was reported independently in 1928 by L'Hermitte.² These initial HSPY operations were utilized as a surgical treatment of cerebral gliomas. The initial optimism of potentially curing malignant gliomas led others to use the procedure for these tumors.³⁻⁷ Other than perhaps a question of an "apparent" transient reduction in tumor growth, reported by a few authors, the results were disappointing. Not only was the growth of the tumor not controlled, but also the quality of survival, often short, was simply unacceptable. Thus, the use of HSPY for the treatment of gliomas was abandoned. However, the legacy of the experience was the demonstration that patients could survive such a radical procedure.

Historical perspectives. Dr. Kenneth McKenzie, in Toronto, in 1938,⁸ was the first neurosurgeon to use this technique for the control of seizures in infantile hemiplegia. The young girl upon whom he operated became totally seizure free. There was no change in her hemiplegia, but she was reported to be physically and mentally much better. It was Krynauw,⁹ however, who

really popularized the operation for seizure control in patients with infantile hemiplegia. He carried out an anatomical hemispherectomy (aHSPY) in 12 patients, removing the entire affected hemisphere, except the thalamus and "tail of the caudate" nucleus. Most of the patients were seizure free and taken off their anticonvulsant medications immediately following operation. However, perhaps the most unexpected benefit of the procedure was a remarkable concomitant improvement in their pre-operative behavioral problems that were nearly uniformly characterized by episodes of rage, or outbursts of temper, or both. This finding was so dramatic in the initial few cases that 2 of Krynauw's 12 patients were operated upon for this reason, even in the absence of seizures! It was his report that resulted in a nearly arithmetic increase in the worldwide use of aHSPY for the treatment of infantile hemiplegia with seizures. The dramatic results demonstrated by Krynauw were soon confirmed by others.^{10,11} Shortly thereafter, recognizing this increasing popularity, Meyers (1958)¹² considered that the ongoing observations provide ample justification for its continual use, so long as such reports continued to objectively record

From the Department of Neurosciences, King Faisal Specialist Hospital & Research Center, Jeddah, *Kingdom of Saudi Arabia*.

Address correspondence and reprint request to: Dr. Saleh S. Baeesa, Division of Neurosurgery, King Abdul-Aziz University Hospital, PO Box 80215, Jeddah 21589, *Kingdom of Saudi Arabia*. Fax. +966 (2) 6408469. E-mail: sbaeesa@kaau.edu.sa

both favorable and unfavorable results and the benefits remained high. Follow-up at this time was less than a decade, but within this short span, it was estimated that some 200-330 cases had been carried out around the world. In these early reports, mention was made of some early complications following surgery, other than the traditional complications of wound infection and blood clots. One of Krynauw's cases died suddenly and unexpectedly during the first post-operative day.⁹ McKissock in 1953,¹¹ reported acute hydrocephalus in 2 of 5 aHSPYs. Cabieses et al,¹³ in 1957 reported a sub acute, eventually lethal, "brain-stem shift" 3 months post-operatively in 2 of their 5 patients who had undergone aHSPYs in the previous 18 months. Their patients underwent a progressive syndrome of lethargy, apathy, mutism, akinesia, incontinence, coma, and death. They emphasized the peculiar type of alteration in consciousness, naming it "psychological stupor," which they felt was most like Cairns akinetic mutism.^{14,15} At post-mortem examination there were some of the classical signs of shift of the remaining hemisphere to the contralateral (operated) side. Although hydrocephalus and other varieties of complications were reported, it was in the 1960s when reports of the late complication of hemorrhage within the post-operative hemicranial cavity began to appear. Observations of this late hemorrhagic complication appeared in the reports of Laine, Pruvet & Ossen in 1964,¹⁶ Oppenheimer & Griffith in 1966,¹⁷ and Falconer & Wilson in 1970.¹⁸ The seriousness of the complication is reflected in the fact that 3 of 20, 4 of 17, and 10 of 50 patients, died as a result of the complication. This seriously compromised the enthusiasm that had been increasing for more than a decade with respect to the outcomes of aHSPY in the treatment of patients with the syndrome of infantile hemiplegia, intractable seizures, and behavioral abnormalities. The patients of Oppenheimer and Griffith all had good post-operative recoveries, only to enter a phase of slow deterioration over years, beginning some years following their operations, ending in death. Post-mortem examinations of 3 of their 4 patients demonstrated obstructive hydrocephalus, combined with superficial hemosiderosis of the central nervous system. They postulated that the latter was due to repeated bouts of intracranial bleeding. These clinical complications and autopsy findings were confirmed by others.¹⁸⁻²⁰ The thesis of Oppenheimer and Griffith that repeated intracranial bleeding was at the basis of the pathophysiology of the hemosiderosis of the central nervous system received support from the experimental work of Iwanowski and Olszewski²¹ who had shown earlier that such hemosiderosis could

be produced in dogs by the repeated subarachnoid injection of autogenous blood and iron-dextran compounds.

Functional hemispherectomy. The increasing recognition and confirmation of the late complications of aHSPY led to a world wide decrease in the number of aHSPYs performed, while at the same time it also led to a flurry of creative initiatives to develop alternative methods for the treatment of infantile hemiplegics with intractable seizures, with the hope of being able to maintain the outcome quality of aHSPY, while simultaneously precluding the complication of superficial cerebral hemosiderosis. These attempts included reduction in size of the large open hemicranial cavity, staging the procedure of aHSPY,²² substitution procedures,⁴ and stereotactic disconnection of the atrophied hemisphere.¹⁶ Rasmussen, in 1973, reported the results of the series of aHSPYs from the Montreal Neurological Institute.²³ He compared total and "subtotal hemispherectomy." The latter group consisted of those patients in whom a large amount of the hemisphere was removed, at either a single operation or from multiple operations, but with some part of the involved hemisphere being left behind. There was a reduction in the success of the operation in patients in whom the hemisphere was not totally resected, but this was more than balanced by the absence of the catastrophic late consequences that followed aHSPY. The foregoing history of aHSPY over the last 70 years has led to the inescapable conclusion that, late complications aside, judicious HSPY is the most efficacious seizure operation available, even though it is relegated largely to small groups of patients. The results of surgery in the control of seizures are impressive and well documented.^{9,20,23,24} Further, there is almost as much success in alleviating associated behavioral problems.^{9,20,22} Finally, patients' intelligence has often been seen to increase,²⁵⁻²⁸ and physically many patients also improve, usually due to decreased clinical spasticity on the affected side. The clinical improvements in these patients are paralleled by the improvements in EEGs, with abolition or suppression of pre-operative dysrhythmias.²⁹ Indeed, the remarkable pre-operative EEG abnormalities, which may exist bilaterally in these patients, may nearly entirely disappear post-operatively.^{5,30} The reason for these observations is somewhat controversial, but perhaps the most popular explanation is that the recorded electrographic abnormalities in the "normal" hemisphere are secondary to, and dependent upon, primary epileptogenic activity in the atrophic hemisphere. The presence of greater abnormalities in the "good" hemisphere have usually been interpreted as being on the basis of the foregoing explanation,

along with the added premise that the damaged hemisphere is so damaged that it cannot express the normal characteristics of epileptogenic discharge. Quite apart from what the exact explanation is for the condition of superficial subpial cerebral hemosiderosis, the facts that are presently available, as discussed so well by Rasmussen,³¹ verify that in the case of aHSPY there is a markedly increased vulnerability of the involved hemicranium to late complications, and more particularly that of superficial cerebral hemosiderosis. Current observations suggest that this can be avoided, if by some means a part of the hemisphere is left in place anatomically. This has given rise to operations in which portions of the hemisphere are anatomically removed, while other portions of the hemisphere are left intact, but physiologically disconnected from the remaining brain – the so-called functional hemispherectomy (fHSPY). The present communication is a description of one such method for performing such a modified HSPY. It has been carried out in over 30 patients, beginning in 1979. The beneficial results of these fHSPYs parallel those of aHSPY and there has been but a single instance of presumed superficial cerebral hemosiderosis, which was successfully treated by transcranial lavage some 10 years ago). The term HSPY literally means a removal of the hemisphere, including the forebrain nuclei, whereas practically, it is an operation of forebrain hemidecortication. Even this is perhaps not perfectly accurate as in many centers the insular cortex is left intact. There is some variation of opinion about potential encroachment upon the forebrain nuclei. Krynauw left only the thalamus and the tail of the caudate intact, as already noted; thus, he removed the lentiform nucleus and presumably the head of the caudate nucleus. The ensuing description is primarily devoted to a consideration of the cerebral mantle of cortex and underlying white matter, and hence perhaps the rather minor controversy of how much caudate nucleus might be removed, if any, and whether the insular cortex should be removed will not be specifically addressed. Further, this communication should not be construed as implying that this is necessarily the best technique of carrying out a fHSPY, nor that it is superior to the more recently introduced technique of hemispherotomy, but rather to provide the description of a technique of fHSPY that has been extremely successfully applied over the course of nearly 25 years.

Surgical technique. The patient is positioned as for a typical temporo-central craniotomy. However, for fHSPY, the most medial part of scalp incision can be variably placed from the midline to as much as lateral to the midline as used for a typical anterior

temporal lobectomy (aTLY). The flap is raised to expose generously the central, or Rolandic, cortex and the temporal lobe (**Figure 1**). The technical difficulty of, or perhaps more accurately, the laboriousness of, the procedure of fHSPY varies according to the etiology. For infantile hemiplegia, with the marked ventricular enlargement, the operation is very easily and quickly carried out. However, in those cases with relatively normal ventricles, and hence relatively normal cerebral mantles, the procedure is more time-consuming. In these cases, the smaller ventricle may be more difficult to find and the upper limb of the “Rolandic window” must be placed at the axial level of the roof of the lateral ventricle. Most of such cases involve patients with so-called Rasmussen’s encephalitis,^{32,33} or cases of hemi-megacephaly. The latter may be even more problematic than the former, with larger cerebral mantles and with often marked neuroanatomical abnormalities, which lead not only to the enlarged mantles, but also with much distorted surgical anatomy. Most of the extended time in these cases is involved in homeostasis. The initial stage of the procedure is a radical temporal lobectomy (TLY). The “radical” aspect of the TLY pertains to its posterior extent. The posterior resection line is made far behind the posterior resection line of the typical aTLY. Ideally, it should be located over the trigone of the ventricle (**Figure 2**). Other than the added posterior extent, it is carried out in the typical manner of a classical aTLY.¹⁴ The second stage consists of a “window” through the whole of the cerebral mantle, removing the central, or Rolandic, area. The lower limb of this “Rolandic window” is the Sylvian fissure in which the whole of the frontal and parietal opercula are removed. The upper limb is located superiorly enough to provide access to the roof of the lateral ventricle, in which a large exposure of the already dilated body of the lateral ventricle is, achieved (**Figure 3**). This is not terribly critical for the hemiatrophic hemisphere, but it is critical for an anatomically normal or enlarged hemisphere, such as usually exists in Rasmussen’s encephalitis and hemimegalencephaly, but rarely in infantile hemiplegia. In this case, the upper limb should be located within 2-3 cm of the midline, making certain that relatively easy access to the roof of the ventricle is obtained. In these cases with the smaller ventricles the lower limb of the incision, which is carried out subpially across the opercula and the insula, will also require more care when subsequently incising the central “stem,” which in essence is through the lower part of the central corona radiata, or the beginning of the formation of the internal capsule. The posterior limb of the window is a superior extension of the posterior resection line

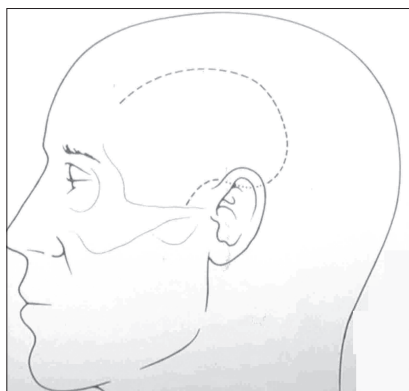


Figure 1 - The scalp flap is large enough to expose the whole of the temporal lobe and the central region, from the sphenoid wing anteriorly to the lateral ventricular trigone posteriorly. The superior limb must be superior enough to allow transventricular access to the underside of the corpus callosum.

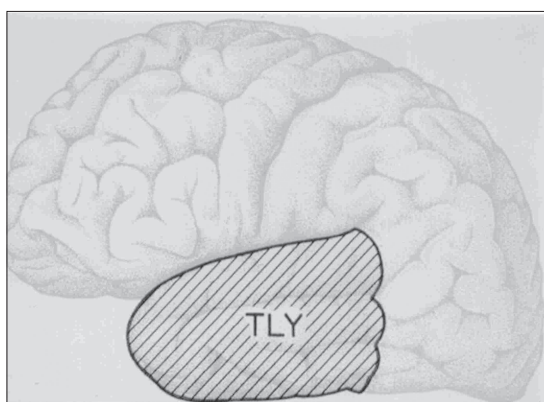


Figure 2 - The initial part (stage 1) of the operative procedure is the radical removal of the temporal lobe. The posterior limb of the resection should be sufficiently posterior to reach the region of the ventricular trigone. TLY - temporal lobectomy.

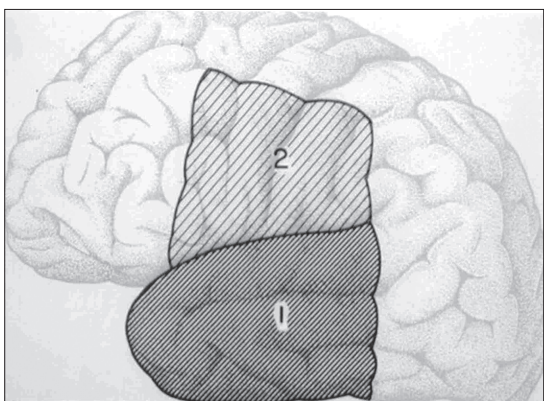


Figure 3 - The second stage involves, after the TLY (1 in the diagram), removal of the central part of the hemisphere, creating a "Rolandic window" (2 in the diagram) into the body of the lateral ventricle. Note: the posterior limb of the "window" is the equivalent of a superior extension of the posterior limb of the TLY.

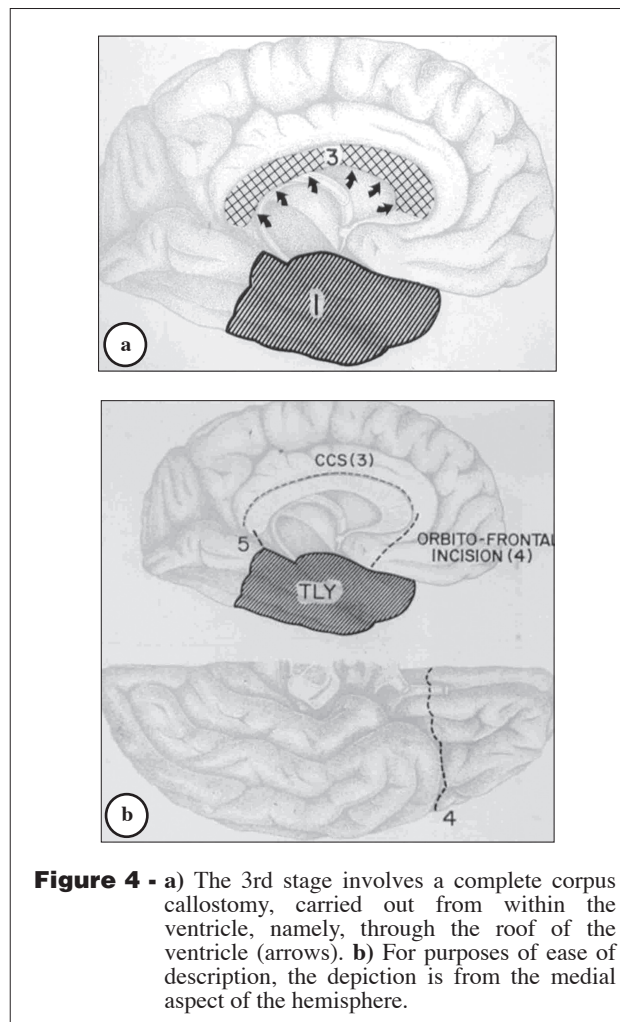


Figure 4 - a) The 3rd stage involves a complete corpus callosotomy, carried out from within the ventricle, namely, through the roof of the ventricle (arrows). b) For purposes of ease of description, the depiction is from the medial aspect of the hemisphere.

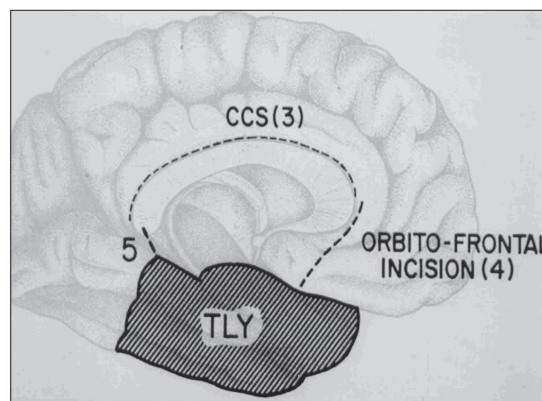


Figure 5 - Stage 4 provides isolation of the frontal lobe by an incision through the posterior orbito-frontal cortical mantle ("4" in B) and then the medial frontal mantle from the genu of the corpus callosum to the posterior-medial aspect of the orbito-frontal incision ("5" in A). (The dorsolateral mid-frontal incision has been made as the posterior limb of the Rolandic "window".) The final, or fifth, stage is achieved by an incision joining the postero-medial aspect of the TLY and the splenium of the corpus callosum ("5" in A), namely, an incision through the mantle of the isthmus.

of the TLY. The anterior limb is over the wing of the sphenoid bone, for example, roughly corresponding to the anterior centimeter or 2 of the temporal fossa and the A1 segment of the anterior cerebral artery. The third stage of the procedure consists of a corpus callosum section (CCS) that is carried out from within the ventricle, as depicted in **Figure 4**. The appropriate plane is identified by a midline, or proximal paramedian, incision through the roof of the ventricle medially, namely, the underside of the corpus callosum. Identifying the pericallosal artery and then following its course minimizes confusion with the anatomy. The incision is carried anteriorly to the genu of the corpus callosum and posteriorly to the splenium. Care must be taken not to cross the midline of the corpus callosum, thus avoiding damage to the contralateral hippocampal outflow. The fourth stage consists of isolation of the frontal lobe. This is achieved by carrying the lower extension of the anterior limb of the "window" medially through the orbito-frontal cerebral mantle to the interhemispheric fissure (**Figure 5**). Using subpial dissection, the larger arteries supplying the orbitofrontal cortex and the olfactory bulb are preserved. The incision line can be located immediately in front of the A1 segment of the anterior cerebral artery. The final isolation of the frontal lobe is achieved by joining the medial aspect of this orbitofrontal incision to the anterior end of the CCS, most easily carried out by following the A2 segment of the anterior cerebral artery. Now, the only remaining anatomical connection is that of the occipital and posterior parietal cortex through a narrow portion ("isthmus") of the antero-medial parietal cortical mantle. The final or fifth stage, isolating this posterior cortex, is achieved by extending the postero-medial aspect of the resection line of the TLY superiorly to join the posterior CCS incision at the splenium (**Figure 5**). The blood supply (arterial and venous) to the isolated brain should be left intact as much as possible.

Is the theoretical basis for a physiological HSPY, which leaves intact some part of the damaged hemisphere, valid? Historically the effects on the good hemisphere of the "bad" hemisphere have been felt to be on a purely neurophysiological basis. Post-operative improvement in cognition, in the EEG on the "good" side, in the alleviation of the associated behavioral abnormalities, and of course the relief of seizures has been interpreted as being partially, or wholly, the result of the removal of the influence of the abnormal epileptogenic discharges of the "bad" hemisphere on the "good" hemisphere. One perhaps must at least consider the possibility of a potentially damaging humoral agent, in the light of the recent burgeoning

literature indicating the ability to transplant central nervous system tissue to treat conditions thought to be caused by a depletion of certain neuro-transmitter substances. This is probably a purely theoretical possibility in the infantile hemiplegic. However, some have expressed concern for fHSPYs carried out for the diagnoses of viral etiology, for example, herpes simplex, or Rasmussen's encephalitis. While there is some evidence for the latter being because of a virus, yet the very ill-understood peculiar fact remains that, the disease is largely confined to one hemisphere, with or without fHSPY. Therefore, the cases of HSPY in which the removal has not been anatomically complete must be reviewed meticulously and cautiously from time to time to be certain that the long-term beneficial effects of the physiological disconnection parallel those of the more classical complete anatomical removal, particularly in the cases of Rasmussen's encephalitis. Putting aside the immediate foregoing, the fact remains that there is reason for optimism now regarding fHSPY carried out partly by physiological disconnection. In the light of the available observations to date, it appears that these types of hemispherectomies would hopefully provide similar benefits, with less risk to patients than the traditional anatomically complete HSPY. While there are various interpretations how remaining functionally isolated cortex might provide the "protection" against the complications of the anatomical HSPYs, yet there is no certain interpretation. It has been our practice to leave as much of the normal blood supply to the remaining disconnected cerebral cortex as possible to maintain its viability. There really is no evidence to scientifically support the necessity for the maintenance of the blood supply to the functionally isolated brain in the fHSPY, however, it is our view that the normal metabolic integrity of this cortex might provide the necessary substrate for whatever it is that leads to the "protection" against the complications of the aHSPY. Thus, the practice of preserving the blood supply is purely empirical.

References

1. Dandy WE. Removal of right cerebral hemisphere for certain tumors with hemiplegia: preliminary report. *JAMA* 1928; 90: 823-825.
2. L'Hermitte J. L'ablation complete de l'hémisphère droit dans les cas de tumeur cérébrale localisée compliquée d'hémiplégie: la decerebration supra-thalamique unilatérale chez l'homme. *Enceph* 1928; 23: 314-323.
3. Austin GM, Grant FC. Physiologic observations following total hemispherectomy in man. *Surgery* 1955; 38: 239-258.
4. Balasubramaniam V, Kanaka TS. Why hemispherectomy? *Appl Neurophysiol* 1975; 38: 197-205.
5. Goodall RJ. Cerebral hemispherectomy: present status and clinical indications. *Neurology* 1957; 7: 151-162.

6. Hillier WF. Total left cerebral hemispherectomy for malignant glioma. *Neurology* 1954; 4: 718-721.
7. Zollinger R. Removal of left hemisphere. Report of a case. *Arch Neurol Psychiatry* 1935; 34: 1055-1062.
8. McKenzie KG. The present status of a patient who had the right cerebral hemisphere removed. *JAMA* 1938; 111: 168.
9. Krynauw RA. Infantile hemiplegia treated by removing one cerebral hemisphere. *J Neurol Neurosurg Psychiatry* 1950; 13: 243-267.
10. Cairns H. Hemispherectomy in the treatment of infantile hemiplegia. *Lancet* 1951; 261: 411-415.
11. McKissock W. Infantile hemiplegia. *Proc Royal Soc Med* 1953; 46: 431-434.
12. Meyers R. Recent advances in the neurosurgery of cerebral palsy. In Illingworth RS, editor. *Recent Advances in Cerebral Palsy*. London (UK): Churchill Livingstone Press; 1958. p. 330-386.
13. Cabieses F, Jeri R, Landa R. Fatal brain-stem shift following hemispherectomy. *J Neurosurg* 1957; 14: 74-91.
14. Cairns H. Disturbances of consciousness with lesions of the brain-stem and diencephalon. *Brain* 1952; 75: 109-146.
15. Cairns H, Oldfield RC, Pennybacker JB, Whitteridge D. Akinetic mutism with an epidermoid cyst of the 3rd ventricle. *Brain* 1941; 64: 273-290.
16. Laine E, Pruvet P, Ossen O. Resultats elloignes de l'hemispherectomie dans les cas d'hemiatrophie cerebrale infantile generatrice d'epilepsis. *Neurochirurg* 1964; 10: 507-522.
17. Oppenheimer DR, Griffith HB. Persistent intracranial bleeding as a complication of hemispherectomy. *J Neurol Neurosurg Psychiatry* 1966; 29: 229-240.
18. Falconer MA, Wilson PJE. Complications related to delayed hemorrhage after hemispherectomy. *J Neurosurg* 1969; 30: 413-426.
19. Mathew NT, Abraham J, Chandy J. Late complications of hemispherectomy: report of a case relieved by surgery. *J Neurol Neurosurg Psychiatry* 1970; 33: 327-375.
20. Wilson PJE. Cerebral hemispherectomy for infantile hemiplegia. A report of 50 cases. *Brain* 1970; 93: 147-180.
21. Iwanowski I, Olszewski J. The effects of subarachnoid injections of iron containing substances on the central nervous system. *J Neuropath Exp Neurol* 1960; 19: 433-448.
22. Griffith HB. Cerebral hemispherectomy for infantile hemiplegia in the light of the late results. *Ann R Coll Surg Engl* 1967; 41: 183-201.
23. Rasmussen T. Postoperative superficial hemosiderosis of the brain, its diagnosis, treatment and prevention. *Trans Amer Neurol Assoc* 1973; 98: 133-137.
24. Hendrick EB, Hoffman HJ, Hudson AR. Hemispherectomy in children. *Clin Neurosurg* 1968; 16: 315-327.
25. Carlson J, Netley C, Hendrick EB, Prichard JS. Reexamination of intellectual disabilities in hemispherectomized patients. *Trans Am Neurol Ass* 1968; 93: 198-201.
26. McFie J. The effects of hemispherectomy on intellectual functioning in cases of infantile hemiplegia. *J Neurol Neurosurg Psychiatry* 1961; 24: 240-249.
27. Smith A, Sugar O. Development of above normal language and intelligence 21 years after left hemispherectomy. *Neurology* 1975; 25: 813-818.
28. Verity CM, Strauss EH, Moyes PH, Wada JA, Dunn HG, Lapointe JS. Long-term follow up after cerebral hemispherectomy: Neurophysiologic, radiologic and psychological findings. *Neurology* 1982; 32: 629-639.
29. Obrador S, Larramendi MH. Some observations on the brain rhythms after surgical removal of a cerebral hemisphere. *Electroenceph Clin Neurophysiol* 1950; 2: 143-146.
30. Torres F, French LA. Acute effects of section of the corpus callosum upon "independent" epileptiform activity. *Acta Neurol Scand* 1973; 49: 47-62.
31. Rasmussen T. Hemispherectomy for seizures revisited. *Can J Neurol Sci* 1983; 10: 71-78.
32. Rasmussen T, Andermann F. Update on the syndrome of "chronic encephalitis" and epilepsy. *Cleve Clin J Med* 1989; 56 Suppl Pt 2: S181-S184.
33. Zupanc ML, Handler EG, Levine RL, Jah TW, ZuRhein GM, Rozenal JM, et al. Rasmussen encephalitis: epilepsy partialis continua secondary to chronic encephalitis. *Pediatr Neurol* 1990; 6: 397-401.
34. Girvin JP. Temporal lobectomy. In: Apuzzo MLP, editor. *Neurosurgical Aspects of Epilepsy. ?Place of Publication? American Association of Neurological Surgeons; 1992. p. 149-158.*