

Conservative Management of Sternal Tuberculosis, Case Report and Review of the Literature

Wail A. Tashkandi, ABGS and **Jehad S. Al Shawi**, FRCSI, FRCS(ED), EBSO
*Department of Surgery, Faculty of Medicine,
King Abdulaziz Medical City, Jeddah, Saudi Arabia
wail_tashkandi@yahoo.com*

Abstract. To present a rare case of a sternal mass mimicking sarcoma, diagnosed as primary sternal tuberculosis; based on a high index of suspicion and managed conservatively. The patient responded completely on a four-drug anti tuberculosis therapy without any surgical intervention.

Keywords: Sternum, Tuberculosis, Osteomyelitis.

Introduction

Tuberculosis is a rare disease in developed countries, although it is endemic in the developing countries especially in Africa and Asia, yet the incidence of musculoskeletal tuberculosis is uncommon; especially the involvement of the sternum as a primary focus, as it is in this case.

Case Report

A 28-year-old male was referred to the surgical clinic with a three months history of a sternal mass (Fig. 1). He is an immunocompetent, newly married with no significant medical or surgical history. This mass increased gradually in size and associated with local pain, fever, night sweats and anorexia. The patient lost around ten kilograms of his body weight. He had a positive family history with a close contact to Pulmonary TB. Clinically, the mass was around 5×5 cm hard; fixed to the sternum and tender. The chest exam was normal and no associated

Correspondence & reprint request to: Dr. Wail Tashkandi
P.O. Box 80295 Jeddah 21589 Saudi Arabia

Accepted for publication: 27 June 2009. Received: 09 June 2009.

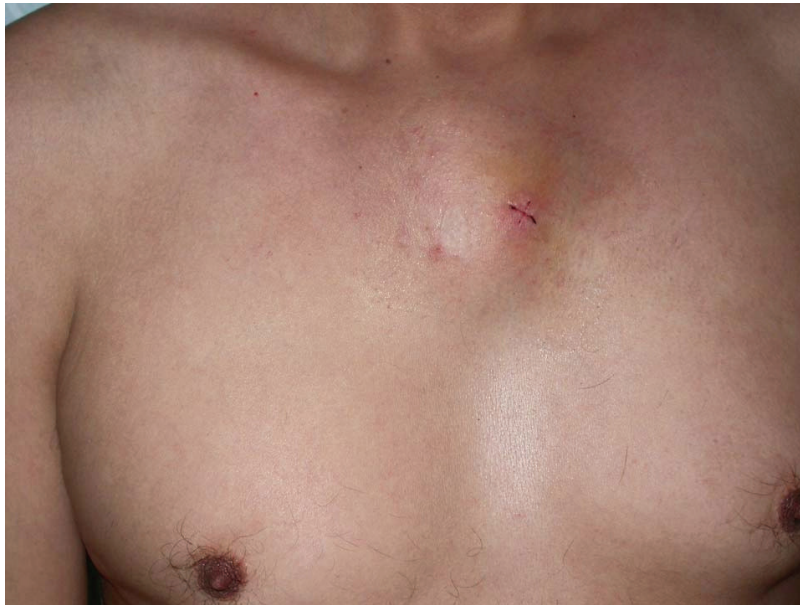

Fig. 1. Shows the sterna mass post true cut biopsy.

lymphadenopathy. The blood work showed normal values apart from high (erythrocyte sedimentation rate ESR) and C reactive protein (CRP). Plain chest (Posteroanterior view) and sternal views X-rays showed no pathology. CT scan of the chest revealed a mass destroying the manubrium, and neither lung pathology nor mediastinal lymphadenopathy was found (Fig. 2). Our provisional diagnosis of primary sternal TB was based on clinical and radiological backgrounds which were confirmed later, microscopically. Our differential diagnosis includes sarcoma of the sternum. True Cut Biopsy was performed and revealed white cheesy discharge. This was sent for Ziehl-Neelsen stain, Lowenstine-Jenhsen medium cultures, Polymerase Chain Reaction (PCR) and cytology. PCR came positive for Mycobacterium TB, and after two weeks, Mycobacterium bacilli were grown in Lowenstine-Jenhsen medium cultures. The patient was started on a four-drug anti TB therapy (Isoniazid, Pyrazinamide, Pyridoxine and Rifampin). The patient was followed up in one to four months; eventually the mass disappeared completely.

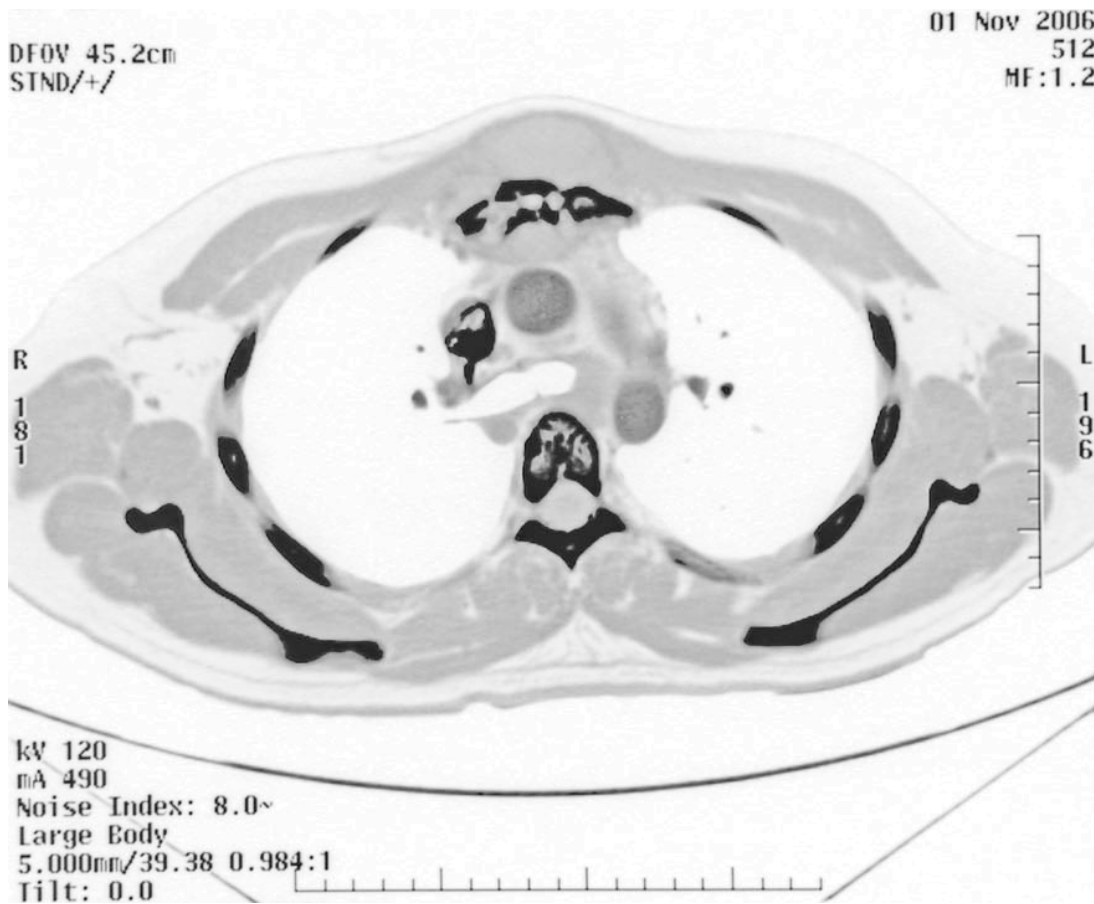


Fig. 2. Shows CT scan chest showing the mass destroying the manubrium sterni.

Discussion

In reviewing the literature, there were few cases reported about sternal TB⁽¹⁻²⁷⁾. Most of these cases were managed aggressively by surgical interventions and reconstructions^(1,8,10,13-15,19,25), while others succeeded with anti-TB agents^(3,4,28-30,)

In this case report, physician managed to use the conservative way and avoiding unnecessary surgery. Statistically, sternal TB occurs only in 1-5 per cent of all bones and joints^[1]. Primary sternal tuberculosis is even more uncommon, such as in this case. Generally, they are young patients, free of underlying disease, and living in a country in which tuberculosis is an endemic.

Sternal TB can be presented as a painful mass at the sternal level with general symptoms of fever, weight loss, and anorexia, thus diagnosing is necessary for a high index of suspicion and to rule out a malignancy^(1,2). However, when there is a high index of clinical suspicion, histologic examination of affected tissues and mycobacterium cultures are necessary^(2,3).

Zhao *et al.*⁽³¹⁾ managed a young immunocompetent woman having a primary sternal TB with extensive debridement and partial sternectomy; followed by musculocutaneous flap closure and long term postoperative antituberculous therapy. Ford *et al.*⁽³²⁾ had successful management of tuberculous osteomyelitis of the sternum with debridement and vacuum assisted closure. Choi *et al.*⁽⁸⁾ managed a case with extensive sternal and chondral resection followed by bilateral pectoralis major muscle flap positioning. Hsu *et al.* suggested that primary chest wall tuberculosis should initially be treated with a combination regimen of antitubercular chemotherapy⁽¹⁹⁾. The successful use of conservative management of primary sternal TB, supports the more conventional way of managing such cases.

In conclusion, primary sternal tuberculosis is a rare disorder worldwide^(1,33) and needs a high index of suspicion for diagnosis; based on clinical, radiological and microscopical backgrounds^(3,5,34). Physicians should always put sternal TB in the list of differential diagnoses of sternal masses mimicking sarcoma. Until now there is no standard treatment. However, it's believed that the conservative management with antituberculous agents should be the first line of treatment; if failure of this treatment, surgical intervention can be considered.

References

- [1] **Mathlouthi A, Ben M'Rad S, Merai S, Friaa T, Mestiri I, Ben Miled K, Djenayah F.** [Tuberculosis of the thoracic wall. Presentation of 4 personal cases and review of the literature] *Rev Pneumol Clin* 1998; **54**(4): 182-6.
- [2] **Shah J, Patkar D, Parikh B, Parmar H, Varma R, Patankar T, Prasad S.** Tuberculosis of the sternum and clavicle: imaging findings in 15 patients. *Skeletal Radiol* 2000; **29**(8): 447-53.
- [3] **Stewart KJ, Ahmed OA, Laing RB, Holmes JD.** Mycobacterium tuberculosis presenting as sternal osteomyelitis. *J R Coll Surg Edinb* 2000; **45**(2): 135-7.
- [4] **Fadiran OA, Akintan B, Oluwole SF.** Tuberculous orchitis co-existing with tuberculosis of the sternum--case report. *Cent Afr J Med* 1999; **45**(2): 45-7.

- [5] **McLellan DG, Philips KB, Corbett CE, Bronze MS.** Sternal osteomyelitis caused by mycobacterium tuberculosis: Case report and review of the literature. *Am J Med Sci* 2000; **319**(4): 250-4.
- [6] **Rasaretnam R, Wijsekera C, Wickramasekera D.** Sternal osteomyelitis. *Ceylon Med J* 1997; **42**(4): 198-9.
- [7] **Kutty S, Bennett D, Devitt A, Dowling FE.** Tuberculous osteomyelitis of the sternum in an infant: a case report and review of the literature. *Pediatr Int* 2002; **44**(2): 186-8.
- [8] **Choi H, Lee CJ, Lee KJ, Moon KD.** Primary tuberculous osteomyelitis of the sternum. *J Cardiovasc Surg (Torino)* 2001; **42**(6): 841-3.
- [9] **Sipsas NV, Panayiotakopoulos GD, Zormpala A, Thanos L, Artinopoulos C, Kordossis T.** Sternal tuberculosis after coronary artery bypass graft surgery. *Scand J Infect Dis* 2001; **33**(5): 387-8.
- [10] **Sarлак AY, Gündeş H, Gündeş S, Alp M.** Primary sternal tuberculosis: a rare unhealed case treated by resection and local rotational flap. *Thorac Cardiovasc Surg* 2001; **49**(1): 58-9.
- [11] **Bohl JM, Janner D.** Mycobacterium tuberculosis sternal osteomyelitis presenting as anterior chest wall mass. *Pediatr Infect Dis J* 1999; **18**(11): 1028-9.
- [12] **Hemmen T, Stölzel U, Höffken G, Vesper J, Sieper J, Distler A, Braun J.** [Costosternal swelling and diffuse bone pain in tubercular osteomyelitis] *Dtsch Med Wochenschr* 1997; **122**(19): 610-4.
- [13] **Aggarwal B, Kamath S, Shatapathy P.** Tubercular sternal osteomyelitis and mediastinitis after open heart surgery. *Indian Heart J* 1997; **49**(3): 313-4.
- [14] **Hajjar W, Logan AM, Belcher PR.** Primary sternal tuberculosis treated by resection and reconstruction. *Thorac Cardiovasc Surg* 1996; **44**(6): 317-8.
- [15] **Lin JC, Miller SR, Gazzaniga AB.** Primary sternal osteomyelitis. *Ann Thorac Surg* 1996; **61**(1): 225-7.
- [16] **Rubinstien EM, Lehmann T.** Sternal osteomyelitis due to Mycobacterium tuberculosis following coronary artery bypass surgery. *Clin Infect Dis* 1996; **23**(1): 202-3.
- [17] **Mulloy EM.** Tuberculosis of the sternum presenting as metastatic disease. *Thorax*. 1995; **50**(11): 1223-4.
- [18] **Mineo TC, Biancari F.** Sternal mass and fever. *Postgrad Med J* 1995; **71**(839): 569-71.
- [19] **Hsu HS, Wang LS, Wu YC, Fahn HJ, Huang MH.** Management of primary chest wall tuberculosis. *Scand J Thorac Cardiovasc Surg* 1995; **29**(3): 119-23.
- [20] **Gatfosse M, Zellner P, Barjonet G.** Tuberculosis of the sternum. Report of a case. *Rev Rhum Engl Ed* 1995; **62**(2): 152-3.
- [21] **Rumbero JC, Pac J, Casanova J.** [Sternal tuberculosis as a unique manifestation of the disease] *Arch Bronconeumol* 1994; **30**(8): 418.
- [22] **Kataria SP, Avasthi R.** Sternal tuberculosis in combination with thalassemia. *J Assoc Physicians India* 1993; **41**(7): 472.
- [23] **Ashour M, Pandya L.** Tuberculosis of the sternum. *Ann Saudi Med* 1990; **10**: 57-59.
- [24] **Rajah R.** Case report 513: Tuberculosis of manubrium sterni. *Skeletal Radiol* 1989; **17**: 601-602.
- [25] **Martos JA, Olm M, Miró JM, Mallolas J, Letang E, Brancos MA, Gatell JM, Soriano E.** [Chondrocostal and chondrosternal tuberculosis in 2 heroin addicts infected with the human immunodeficiency virus] *Med Clin (Barc)* 1989; **93**(12): 467-70.
- [26] **Kalra OP, Sharma BK, Banerjee CK, Khosla VK.** Sternal involvement in disseminated tuberculosis. *J Assoc Physicians India* 1988; **36**(4): 292-3.
- [27] **Watts RA, Paice EW, White AG.** Spontaneous fracture of the sternum and sternal tuberculosis. *Thorax* 1987; **42**(12): 984-5.

- [28] **van Loenhout-Rooyackers JH, Veen J.** Treatment of pulmonary tuberculosis. *Neth J Med* 1998; **53**(1): 7-14.
- [29] **Fanning A.** Tuberculosis: 6. Extrapulmonary disease. *CMAJ* 1999; **160**(11): 1597–1603.
- [30] **American Thoracic Society Documents.** American Thoracic Society/Centers for Disease Control and Prevention/Infectious Diseases Society of America: treatment of tuberculosis. *Am J Respir Crit Care Med* 2003; **167**: 603–662.
- [31] **Zhao X, Chen S, Deanda A Jr, Kiev J.** A rare presentation of tuberculosis. *Am Surg* 2006; **72**(1): 96-7.
- [32] **Ford SJ, Rathinam S, King JE, Vaughan R.** Tuberculous osteomyelitis of the sternum: successful management with debridement and vacuum assisted closure. *Eur J Cardiothorac Surg* 2005; **28**(4): 645-7
- [33] **Rachid K, Chkoura M, Moudene A.** [Rare localizations of bone tuberculosis. Three case reports] *Rev Chir Orthop Reparatrice Appar Mot* 2001; **87**(2): 176-9.
- [34] **Atasoy C, Oztekin PS, Ozdemir N, Sak SD, Erden I, Akyar S.** CT and MRI in tuberculous sternal osteomyelitis: a case report. *Clin Imaging* 2002; **26**(2): 112-115.

العلاج التحفظي لدرن عظمة القص ، تسجيل حالة ومراجعة الحالات

وائل عبدالحفيظ طاشكندي، و جهاد صادق الشاوي

قسم الجراحة ، كلية الطب، جامعة الملك عبدالعزيز

جدة - المملكة العربية السعودية

المستخلص. نقدم حالة نادرة لكتلة في عظمة القص تحاكي الورم السرطاني، شخّصت فيما بعد بدرن عظمة القص. كان التشخيص مبني على الاشتباه الاكلينيكي، وتمت معالجة الحالة تحفظيا بالأدوية المعالجة للدرن، وتمائل المريض للشفاء الكامل بدون أي تدخل جراحي.